

## Dissociation of Cortical and Single Unit Activity in Spoken and Signed Languages

MICHAEL M. HAGLUND,\* GEORGE A. OJEMANN,\*<sup>1</sup> ETTORE LETTICH,\*  
URSULA BELLUGI,† AND DAVID CORINA†

\**Department of Neurological Surgery, RI-20, University of Washington, Seattle, Washington 98195; and †Laboratory for Cognitive Neuroscience, The Salk Institute for Biological Studies, La Jolla, California 92037*

Based on stroke and other lesion data, the cortical organization of sign language has been shown to be in the verbal language-dominant hemisphere. However, finer detail of the cortical organization of sign language is not readily available. Intraoperative cortical mapping of spoken and American Sign Language (ASL) was performed in a hearing patient proficient in ASL undergoing an awake operation for intractable epilepsy. We found the dissociation of essential cortical language sites for spoken and signed languages, the relationship of these sites to the interpretation of ASL, and the importance of the anterior temporal lobe in the language-dominant hemisphere for proper ASL handshapes. Single unit recordings in the anterior temporal lobe, at a site later identified to be important in handshape formation, showed sustained activity during naming with superimposed increases in activity during overt speech. © 1993 Academic Press, Inc.

### INTRODUCTION

The neurobiology of language has usually been investigated in the context of spoken language and the writing systems which represent them. A different approach has recently surfaced in investigations of languages which have arisen outside of the mainstream of spoken languages, the signed languages of deaf people. Research into signed languages has revealed that there are primary linguistic systems passed down from one

Michael M. Haglund was supported by the American Epilepsy Society and the American Association of Neurological Surgeons Research Foundation Fellowships; George Ojemann was supported by NIH NS 21724, 17111, and 20483; Ursula Bellugi was supported by NIH DC 00146, 00201, and HD 132249. The authors thank David Cawthon for his technical assistance in making the stereotrodes; Doug Kalk for designing the computer analysis package for single unit recordings; and Freda Norman and Lucinda Batch for their assistance in analyzing the sign language responses.

<sup>1</sup> To whom correspondence should be addressed.

Ojemann, 1990, 1991). These intraoperative investigations of oral language have utilized electrical stimulation mapping to identify essential areas and record changes in electrocorticographic and single neuronal activity to identify physiological correlates of language tasks (for reviews, Ojemann, 1990, 1991). Cortical stimulation activates or blocks neurons in a very local region of cortex (Haglund & Blasdel, 1992; Haglund, Ojemann, & Blasdel, 1991). These stimulation studies indicate that language cortex is compartmentalized into different systems for different language functions such as object naming or reading, including naming in different oral languages (Ojemann, 1983, 1990, 1991). Each system includes several essential areas in the frontal and temporoparietal cortex and widely dispersed neurons, such that the entire system is activated in parallel during the appropriate language function.

Intraoperative investigation of the cortical organization of manual communication systems has previously been reported for only two cases, both electrical stimulation mapping studies in hearing patients, one of finger

spelling in dominant hemisphere (Mateer, Polen, Ojemann, & Wyler, 1982) and the other of ASL in non-language-dominant cortex (Mateer, Rapport, & Kettrick, 1984). The present report provides the first data on localization of essential areas for reception and expression of ASL in a hemisphere known to contain oral language and the first microelectrode recording of human neuronal activity during expression of ASL as well as oral language.

## METHODS

*Subject.* This study was performed in a 26-year-old right-handed hearing woman, a native English speaker, who learned ASL as a young child to communicate with her congenitally deaf sister. She had onset of medically intractable seizures at age 7. Subsequent evaluation demonstrated a left anterior frontotemporal epileptic focus, without evidence of a structural lesion. On the intracarotid amobarbital perfusion test, left carotid artery injection produced no speech blockage, but a significant increase in object naming and reading errors. Right carotid injection produced a short period of speech blockage, a series of object naming errors, and slight increase in reading errors. Thus, both hemispheres were related to spoken language with significantly more reading localized in the left hemisphere.

*Cortical stimulation mapping.* The evening prior to surgery the patient viewed a series of slides to which she responded with either spoken or signed (ASL) language. The slides consisted of both inanimate and animate objects that could be signed with her left hand only (milk, frog) in the operating room. The patient gave informed consent for both the surgical procedure and the single unit recordings. During her responses in ASL to the series of slides, she was videotaped for replay in the operating room to test her ability to interpret sign language and respond verbally.

The patient was taken to the operating room and an awake left frontotemporoparietal craniotomy was performed under local anesthesia (Fig. 1A) (Ojemann, 1985). Surface electrical stimulation was performed during randomly selected slides under each of the behavior conditions at the same multiple perisylvian cortical sites (see Fig. 1B for location of these sites). Bipolar stimulation consisted of 4-sec trains of biphasic square wave pulses (1-msec pulse width) at 60 Hz delivered through 1-mm-diameter silver ball electrodes separated by 5 mm (Ojemann et al., 1989; Ojemann, 1990, 1991). A current 1 mA below the threshold for afterdischarge, 7 mA between the peaks of the pulses, was used for cortical mapping.

The patient viewed a series of 12 slides for object naming with spoken or signed language and then viewed the videotape of herself signing during which she interpreted the sign and responded verbally. Cortical stimulations were performed randomly at multiple cortical sites (see numbered areas for cortical sites tested, Fig. 1B). Nonstimulation error rates were 0% (0 errors/85 stimulations) for spoken object naming, 3% (1/36) for signed object naming, and 4.5% (1/22) for sign interpretation with spoken responses. All the patient's responses were videotaped for later evaluation by both hearing and deaf signers experienced in ASL (Bellugi, Corina, Norman, & Batch). The videotape of her signed responses was evaluated independently of the stimulation information and divided into major errors (omissions, clear movement errors) and minor errors (phonetic level errors, i.e., weakened articulation for handshapes or laxing) (Bellugi et al., 1989, 1990; Klima and Bellugi, 1979).

*Single unit recordings.* During the single unit recording, the patient viewed an identical series of slides that required responses overtly, silently, or with ASL. The tasks consisted of object naming and a spatial match (Ojemann, 1983). The slides had an object to be named and a single red line at different orientations. Before presentation of the series of slides, the patient was instructed to name the slide orally, silently, or with ASL. In the spatial task these same slides alternated with a second slide that had only a red line at

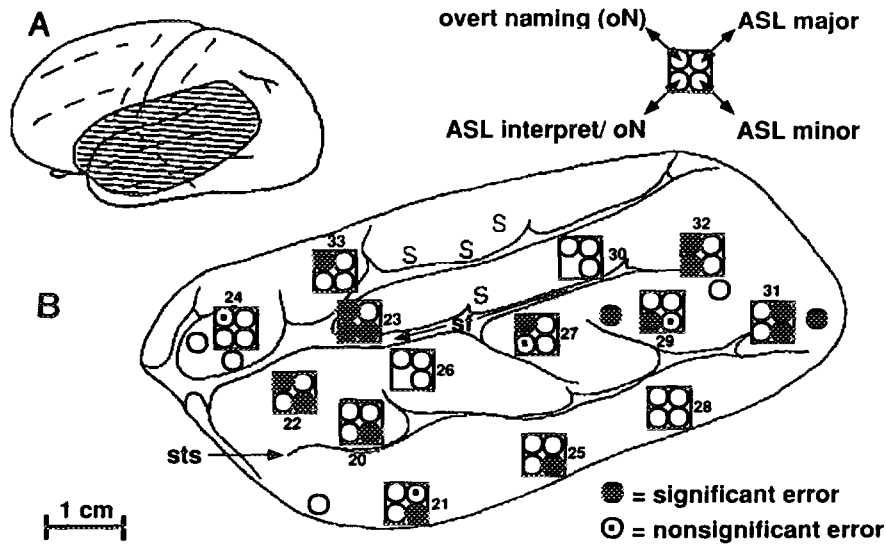


FIG. 1. (A) The hatched area of cortical exposure during the operation. This region is enlarged with more detail in B. (B) Cortical region mapped for different modalities including oral and sign languages and sign language interpretation. sf, Sylvian fissure dividing the temporal (inferior) from the frontal and parietal lobes (superior) which are to the left and right, respectively; sts, superior temporal sulcus. The numbered boxes are the sites of cortical stimulation. The single circles represent sites where only spoken object naming was tested. Completely filled circles represent areas where significant errors were found ( $p < 0.05$  single sample binomial probability). Partially filled circles are sites where errors occurred but did not reach significance.

certain orientation. The patient was instructed to respond either "yes" or "no" overtly in English or with ASL if the line matched the previous slide.

The single unit analysis consisted of digitizing the analog recordings at 10 mHz. A well-isolated unit was identified as was the voice and slide trigger digitized data. The average verbal response was at  $1.2 \pm 0.21$  sec. Therefore, all verbal responses occurred during the epoch between 1.0 and 1.5 sec after the slide appeared. The average single unit activity was calculated for each 500-msec epoch after the slide appeared. Significant results were based on individual trials using a Wilcoxon signed rank tests with a  $p$  value of  $< 0.05$  (Ojemann, Creutzfeldt, Lettich, & Haglund, 1988).

## RESULTS

### *Cortical Stimulation Mapping*

During the awake left craniotomy under local anesthesia, cortical stimulation at frontal site 23 evoked an arrest of oral counting, errors in spoken object naming and spoken responses to sign interpretation. These findings relate site 23 to motor speech output (Broca's area). This area was also associated with minor phonetic errors in signing.

Elsewhere, there was a clear dissociation of cortical sites essential for

spoken and signed object naming and the interpretation of signed language with verbal responses. In the overall cortical map, five sites showed this dissociation (sites 27, 29, 31, 32, and 33). Site 32 is a cortical site where spoken object naming was interrupted but signing was normal (it is unknown if sign interpretation with spoken responses was affected since there was speech arrest). Signing was altered at site 31 but both spoken object naming and sign interpretation were unaffected. Sites 27 and 33 are cortical areas where spoken object naming was interrupted by cortical stimulation; however, signing and interestingly sign interpretation with *verbal responses* were normal. Thus, although the patient could not name the object in English, she could still speak the word as part of the sign interpretation task. The opposite result occurred at site 29 where the patient was unable to interpret her sign but could still name the object with her spoken language.

When the videotape of the patient signing was reviewed after the operation, cortical stimulation mapping of the anterior temporal lobe evoked multiple minor errors in sign handshapes. The errors were located in both the anterior and the middle temporal lobes. In the anterior temporal lobe at sites 20, 21, 22, and 25, minor errors in handshapes occurred in 13 of the 15 stimulations.

#### *Single Unit Recordings*

The dissociation of spoken from signed language was also evident in the single neuronal recording, obtained at site 20 in the superior temporal gyrus, 1 mm below the surface (Fig. 1B). Neuronal activity clearly increases with overt naming compared to that with silent naming, naming by signing, or when viewing the same slides as part of the spatial task (first slide of spatial task, Fig. 2A). The dramatic increase in neuronal activity during overt naming decreased quickly when instructions for the next task were given. Further decreases in the neuronal activity occurred when the silent naming started.

The single unit activity increased significantly while viewing the first slide of the spatial signing task in preparation of a yes/no response with signing for line matching in the second slide (Fig. 2B). Also, during signed yes/no responses in the spatial matching task neuronal activity was significantly increased compared to that with overt yes/no responses in the spatial task (Fig. 3). Notably, cortical stimulation at that site produced problems with accurate handshapes.

## DISCUSSION

#### *Cortical Stimulation Mapping*

This case extends previous observations, indicating that language cortex is compartmentalized into largely separate systems for different language

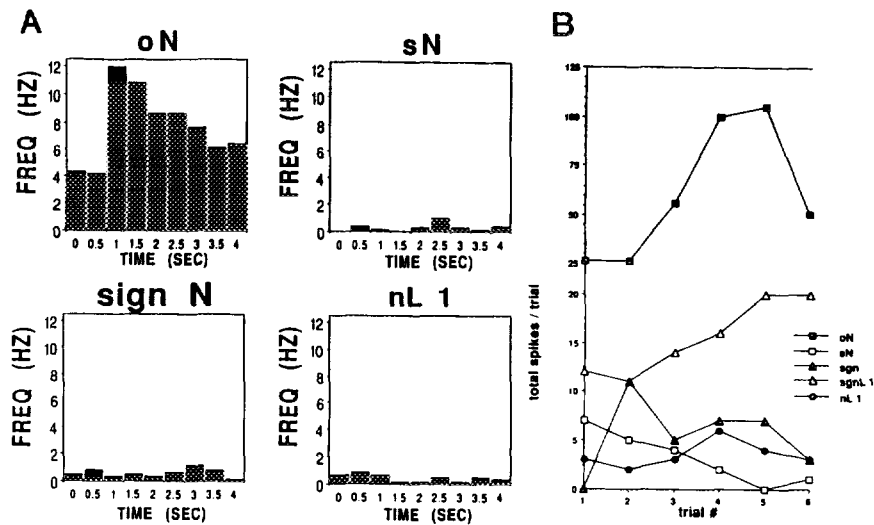


FIG. 2. (A) Single unit firing frequency histograms for different language and signing tasks. Each histogram represents the average of six trials divided into 500-msec bins of activity. During the overt naming (oN), the unit activity greatly increased compared to the activity during the same slide presentations as part of silent naming (sN), signing (sign N), or overt naming as part of a spatial task (nL 1). The increase during the overt naming was potentiated during the verbal output portion at 1–1.5 sec. (B) Total neuronal activity during the first 3 sec of the six trials. All slides contained the same visual stimulus (an object with a red line across the object) but a different behavioral measure was tested. The total activity of the overt naming (oN) is significantly greater than all other measures. However, the first slide of the spatial task (silent response in preparation of the yes/no signed response for line matching during the second slide, sgnL 1) was significantly greater than the other three measures (nL1, overt naming of the first slide of a pair of spatial task slides that requires a yes/no output for line matching in the second slide; sN, silent naming; sgn, naming with signed language). The area (Fig. 1B, site 20) of the single unit recording was later identified to be involved in minor errors with handshapes by cortical stimulation mapping.

functions including separate systems for oral and ASL naming and perception of ASL names. As in the previous observation of a separate system for naming or word reading in one language, or naming the same objects in two different languages, this separation involves both essential areas and more widely dispersed neuronal activity (Ojemann, 1990, 1991).

The present case provides insights into the cortical localization of essential areas for manual communication systems in the language-dominant hemisphere. Although the frontal speech area, Broca's area, has often been considered to be involved with orofacial movement related to speech production (Ojemann & Creutzfeldt, 1989; Ojemann, 1983), lesions there also are associated with deficits in written output (Ojemann, 1991), so it is perhaps not surprising that ASL deficits were also evoked there. Broca's

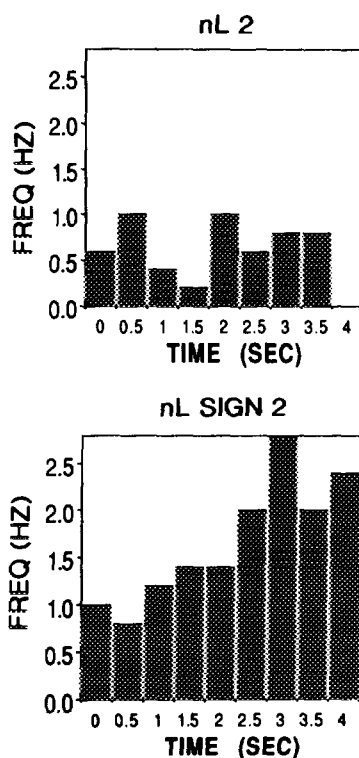


FIG. 3. Single unit average firing frequency histograms (six trials) for the second slide of the spatial task. The patient responded either yes/no overtly (nL 2) or yes/no by signing (nL SIGN 2) as to whether the line matched that of the previous slide. The neuronal activity is greater during the signing yes/no as part of the spatial task than during the spoken yes/no of the spatial task. The increase in firing is primarily during the last 2 sec. These changes in neuronal activity during signing are at a cortical site where stimulation caused minor errors in handshapes.

area then should be viewed as important to language motor output, regardless of whether orofacial or limb movements are involved in output.

In the present case, errors in ASL production were particularly likely from anterior temporal sites (13/15), while errors in oral language were rarely evoked at these sites. The previous case of mapping of finger spelling also showed sites essential for only finger spelling and not oral language in anterior temporal lobe (Mateer et al., 1982). In that case, resection of those sites resulted in a specific deficit in finger spelling. Together, these cases suggest that the anterior temporal lobe of the language-dominant hemisphere has a special role in manual communication systems, a role that is less evident in oral language.

### *Single Unit Recording*

A pattern of increased single unit neuronal activity for predominantly oral language was observed in the present case. The sustained increase in neuronal activity throughout the task abruptly decreasing with a new task is similar to that observed in other cases for other language functions. In the present case, a slight further increase in activity at the actual time of speech output (1.0–1.5 sec, Fig. 2A) seems to be superimposed on the sustained increase. This is the first evidence that patterns of activity temporally related to a language task can occur in the same neuron that shows sustained overall shifts in activity with that task.

Understanding the role of a neuron in different language tasks is limited by the range of functions measured during the recording, constrained by the time available for intraoperative assessment. Most previous recordings have shown significant changes with only one measured function, although a few have shown changed activity with multiple tasks (Ojemann et al., 1988). The findings here of significant increases in activity with one measure of ASL production, although at a level much below that for oral language, indicate that at least some neurons have major and minor roles in different language functions. The absence of changes with other tasks (such as ASL naming or spatial matching with verbal output) which required at least as much perception and attention as oral naming indicates the absence of nonspecific changes in neuronal activity.

Finding individual anterior temporal lobe neurons that demonstrate changes in activity in response to different language tasks suggests a distributed neuronal system for language. The distributed nature of the cortical organization of language was also evident from the mapping of sign language in this patient. Large regions of the anterior temporal lobe obviously play a role in accurate handshapes. The dissociation of cortical sites essential for overt naming, sign language, and interpreting sign language points to the distributed nature of the cortical organization of language.

### REFERENCES

- Bellugi, U. 1991. Language and cognition: What the hands reveal about the brain: Presidential special address. *Society of Neuroscience Abstracts*, **17**, 581.
- Bellugi, U., Poizner, H., & Klima, E. S. 1989. Language, modality, and the brain. *Trends in Neuroscience*, **12**, 380–388.
- Bellugi, U., Poizner, H., & Klima, E. S. 1990. Mapping brain functions for language: Evidence from sign language. In G. M. Edelman, W. E. Gall, & W. M. Cowan (Eds.), *Signal and sense: Local and global order in perceptual maps*. New York: Wiley-Liss.
- Damasio, A., Bellugi, U., Damasio, H., Poizner, H., & Van Gilder, J. 1986. Sign language aphasia during left-hemisphere Amytal injection. *Nature*, **322**, 363–365.
- Haglund, M. M., & Blasdel, G. G. 1992. Video imaging of neuronal activity. In J. A. Stamford (Ed.), *Monitoring neuronal activity: A practical approach*. New York: Oxford Univ. Press.



- Haglund, M. M., Ojemann, G. A., & Blasdel, G. G. 1991. Video imaging of bipolar cortical stimulation. *Epilepsia*, **32**(Suppl 3), 22.
- Klima, E. S., & Bellugi, U. 1979. *The signs of language*. Cambridge, MA: Harvard Univ. Press.
- Mateer, C., Polen, S. B., Ojemann, G. A., & Wyler, A. R. 1982. Cortical localization of finger spelling and oral language: A case study. *Brain and Language*, **17**, 46–57.
- Mateer, C. A., Rapport, R. L., & Kettrick, C. 1984. Cerebral organization of oral and signed language responses: Case study evidence from Amytal and cortical stimulation studies. *Brain and Language*, **21**, 123–135.
- Ojemann, G. A. 1983. Brain organization for language from the perspective of electrical stimulation mapping. *Behavioural Brain Sciences*, **2**, 189–230.
- Ojemann, G. A. 1985. Surgical treatment of epilepsy. In R. H. Wilkins & S. S. Rengachary (Eds.), *Neurosurgery*. New York: McGraw–Hill.
- Ojemann, G. A. 1990. Organization of language cortex derived from investigations during neurosurgery. *Seminars in Neuroscience*, **2**, 297–305.
- Ojemann, G. A. 1991. Cortical organization of language. *Journal of Neuroscience*, **11**, 2281–2287.
- Ojemann, G. A., & Creutzfeldt, O. D. 1989. Language in humans and animals: Contribution of brain stimulation and recordings. In F. Plum & S. Geiger (Eds.), *Handbook of Physiology, Nervous System V, Part 2*. Bethesda, MD: American Physiological Society Press.
- Ojemann, G. A., Creutzfeldt, O. D., Lettich, E., & Haglund, M. M. 1988. Neuronal activity in human lateral temporal cortex related to short-term verbal memory, naming, and reading. *Brain*, **111**, 1383–1403.
- Ojemann, G. A., Ojemann, J. G., Lettich, E., & Berger, M. 1989. Cortical language localization in the left, dominant hemisphere. *Journal of Neurosurgery*, **71**, 316–326.
- Petitto, L. A., & Marentette, P. F. 1991. Babbling in the manual mode: Evidence for the ontogeny of language. *Science*, **251**, 1493–1496.
- Poizner, H., Bellugi, U., & Klima, E. S. 1990. Biological foundations of language: Clues from sign language. *Annual Reviews Neuroscience*, **13**, 282–307.